

## A Novel Approach to SKULL BASE TUMORS

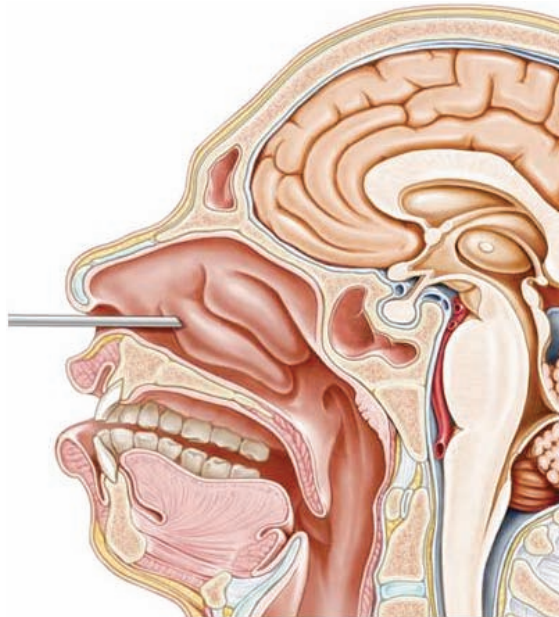


framed black and white drawing hangs on the wall of James Liu's office in the Doctors Office Center on UMDNJ's Newark campus. It depicts a physician performing brain surgery in the early 1900s. But instead of cutting through the patient's skull, this surgeon approaches the brain in a most ingenious way: through the nose.

"This is Dr. Harvey Cushing, the most famous physician in our field," says Liu, pointing to the drawing. "He's the Vince Lombardi of neurosurgery. While he didn't invent this procedure, he paved the way for its success. He did transnasal surgery for pituitary tumors before anybody else." In the drawing, Cushing wears a light on his head, akin to a coal miner. "Using a flashlight, he's looking at the brain with his naked eye!" adds Liu. "Things are a lot different now, thanks to technology."

Fast-forward to the present as Liu, director of skull base and pituitary surgery at UMDNJ-University Hospital (UH), follows in Cushing's footsteps with collaborator Jean Anderson Eloy, MD, director of rhinology and endoscopic sinus surgery at UH. The two make an intriguing team. While their specialties are vastly different, they frequently occupy the same real estate: the base of the skull.

"We deal with pathologies that arise on the bottom of the brain," says Liu. "Many of the major arteries and nerves exit the skull here to give life and movement to the head and neck. It's very difficult to reach this area."



IN THIS UNIQUE SURGICAL PROCEDURE, THE ENDOSCOPE REACHES THE BOTTOM OF THE BRAIN THROUGH THE NOSTRILS, AVOIDING INCISIONS TO THE SKULL OR FACE.

Liu holds up a model of a human skull. "How does one get to the center of the brain, the center of one's soul?" he asks. "It's challenging and fascinating, and that's what led me to study it."

The major surgical problems in this part of the brain are tumors, including pituitary tumors, acoustic neuromas, meningiomas, cranio-pharyngiomas, and chordomas. "They can range in size from one centimeter — very tiny — to five or six centimeters, the size of a golf ball," comments Liu. Traditional removal involves open surgical procedures, such as a craniotomy (transcranial) or a transfacial approach, which requires cutting through the skull or face. Some tumors, depending on the location and size, can be removed transnasally through the natural orifices of the nostrils without any incisions on the face. This latter procedure is often referred to

as the endonasal endoscopic approach.

"We remove the tumors using a minimally invasive technique," explains Liu, turning his computer screen to show a video of a recent surgery. The image on the screen is remarkably vivid, depicting a

large compressive skull base tumor appearing as an ominous-looking red bulge. “I document all my important cases with video and photography,” Liu continues, pointing. “This is the tumor, pressing on the optic nerve. In this picture, the tumor’s gone. And here’s the optic nerve. It’s now free of compression.”

The latest innovation in skull base surgery utilizes the endoscope, a thin telescope with a camera on the end that fits through the nostril. That’s where Eloy comes in. An NJMS alum, he did a fellowship in rhinology and sinus surgery at the University of Miami before coming to NJMS in 2008. His mentor at Miami, Roy Casiano, MD, established an endoscopic skull base lab for his fellows. “The old way of doing it was with a traditional microscope, but the endoscope is much better,” says Eloy. “It gives more light, and it can be angled at 30 degrees or 70 degrees, allowing us to see around corners.”

While many academic health centers are using endoscopic technology to remove pituitary tumors transnasally, Liu and Eloy have taken the procedure several steps farther. “We’re probably the only combined endoscopic skull base team in New Jersey doing transnasal surgeries for complex tumors such as meningiomas, craniopharyngiomas, and esthesioneuroblastomas,” says the neurosurgeon. “We are also performing endonasal odontoidectomies to decompress the brainstem and spinal cord in patients who have craniocervical junction abnormalities.”

The endonasal approach to the brain is a delicate dance. “First we open the sinuses to reach the base of the skull,” explains Eloy. “We then drill through the bottom of the skull to access the tumor at the base of the brain. Sometimes there are up to four instruments in the nostrils, including the endoscope, suction, and our surgical tools. They’re all tiny, so it works well.”

Serendipity brought the two surgeons together at NJMS, where both are assistant professors, Liu in the Department of Neurological Surgery and Eloy in the Department of Surgery, Division of Otolaryngology. When Liu was recruited from the faculty at Northwestern University in 2009, he asked if there was a rhinologist on staff who could be part of an endoscopic transnasal surgery team. He was told about Eloy.

“I didn’t start using the endoscope to remove more complex tumors until I was practicing on my own in Chicago,” says Liu. Over the past year, he and Eloy have tested brand-new technology — a 3D endoscope that provides an even clearer view into this part of the brain. Thus far, Liu has performed eight 3D procedures. One of these patients is Ana Cores, a 52-year-old social worker from Hackensack. In February 2010, she noticed she was losing her sight, particularly her peripheral vision. By April, she couldn’t see at all out of her left eye. “I was really frightened,” she



PATIENT **ANA CORES** IS THE PICTURE OF GOOD HEALTH FOLLOWING THE INNOVATIVE PROCEDURE PERFORMED BY **JAMES LIU, MD** (CENTER), AND **JEAN ANDERSON ELOY, MD**.

says. “It happened so quickly.”

Cores was diagnosed with a craniopharyngioma, a type of tumor derived from pituitary gland embryonic tissue. It pressed on her optic nerve, causing the vision loss. “My daughter’s friend, a surgeon, met Dr. Liu while doing a residency at UMDNJ and highly recommended him,” says Cores. When Cores came to see Liu, he told her he thought she’d be a good candidate for the minimally invasive endonasal endoscopic procedure. She was “relieved to learn that I would not have to have my skull or face cut open.”

Cores had her surgery on May 7, the first patient in New Jersey to have a craniopharyngioma removed via 3D endoscopic technology. Following the nine-hour procedure, “I felt very good, apart from a slightly stuffy nose. My vision improved immediately. It’s getting better every day and I’m now able to read, watch TV and use my computer, all things I could not do before.” She plans to return to work soon.

Another patient, Arlene Kwisnek, came to Liu with a large tuberculom sellae meningioma — a tumor that frequently affects vision. It was compressing her optic nerves and frontal lobes, leaving her almost blind in the left eye. She works in accounting for Verizon, so her situation was particularly worrisome “because I sit at a computer all day long — only now I couldn’t see the computer.” Adding to her concern, her mother had the same type of meningioma at age 83 and suffered from memory impairment.

Kwisnek’s tumor was removed in mid-August in a 14-hour operation. “It was a stubborn, tricky tumor,” she says. “Nine hours into the procedure, they still hadn’t removed it.”

“Because this tumor was very firm, our usual tools weren’t powerful enough to debulk it,” explains Liu, referring to the process of removing the inside of a tumor so the shell collapses like an empty paper bag. “I had to think outside the box and come up with a creative solution. I ended up using a microdebrider, a tool for sinus surgery, to remove the tumor’s firm core. That did the trick and allowed for easy collapse and delivery of the rest of the tumor.” Immediately after surgery, Kwisnek’s vision improved dramatically.

“I don’t think ‘miracle’ is too strong a word to describe my recovery,” says Kwisnek.

Turning his computer screen once again, Liu shows a PowerPoint slide presentation. It features the patient’s before-and-after brain scans and photos of her tumor removal. The last slide, taken a day after surgery, shows the patient sitting in her hospital bed smiling. She doesn’t look as though she’s just had brain surgery. The caption reads: “No Incisions. No Craniotomy. Happy Patient.”

“This is my passion,” says Liu, smiling himself. “It’s exciting to be here doing this innovative work.” ■